

ANTROPOLOGIA PORTUGUESA

●
*Estudos
de
Antropologia
Física*

Vol. 8
1990

MUSEU E LABORATÓRIO ANTROPOLÓGICO
UNIVERSIDADE DE COIMBRA

**EPIPHYSEAL FUSION AT THE STERNAL END
OF THE CLAVICLE
IN A MODERN PORTUGUESE SKELETAL SAMPLE.**

S. M. MacLaughlin

*Department of Anatomy, United Medical and Dental Schools, Guy's Campus,
London Bridge, London SE1 9RT.*

RESUMO. Utilizando uma amostra de clavículas seleccionadas duma colecção de esqueletos de Lisboa, estudou-se uma série progressiva de modificações relacionadas com a idade na extremidade média da clavícula. As modificações na morfologia clavicular puderam ser detectadas aos 15 anos de idade, quando um sistema de sulcos bem distinto começou a ossificar. Por volta dos 20 anos, surgiu uma linha epifisiária e iniciou-se a fusão com a diáfise. Aos 24 anos a epífise estava quase totalmente fechada e a fusão completa era observável em todos os indivíduos que morreram com mais de 25 anos. Os nossos resultados sugerem que os de outros autores têm subestimado o valor deste método como ajuda na identificação da idade à morte de adultos jovens.

Palavras chave: clavícula, determinação da idade.

SUMMARY. Using a sample of clavicles selected from the skeletal collection housed in Lisboa, a series of progressive age related changes were encountered at the medial end of the clavicle. Changes in clavicular morphology could be detected at 15 years of age, when the distinct ridge and furrow system of the epiphyseal surface began to infill. By 20 years of age an epiphyseal flake was present and had commenced fusion with the diaphysis. By 24 years of age the epiphysis had almost completed fused and total fusion was present in all individuals older than 29 years of age at death. This suggests that results from previous workers may be foreshortening the value of this method as an aid to the identification of age at death in young adults.

Key-words: Clavicle, medial epiphysis, age at death.

INTRODUCTION

The timing of the appearance of centres of ossification and subsequent epiphyseal union is often the only information available to osteologists whereby the age at death of a sub-adult human skeleton can be assessed. Krogman (1962) stated that «As a general rule... ageing of bones is more precise with respect to appearance of centers of ossification than it is with respect to union of epiphyses». However, information concerning the timing and sequence of epiphyseal union is invaluable for the determination of age at death in adolescent or young adult individuals.

There is some debate with regards to the first epiphysis to fuse, but the consensus is that in the majority of bones, fusion will commence at around 12-14 years in females, being delayed by some two years in males (Krogman and Iscan 1986). However, it can be said that the period of life between 15 and 20 years is pre-eminently the period of epiphyseal union.

The medial end of the clavicle has long been recognised as the final diaphysio-epiphyseal union to occur (Stevenson 1924; Todd and D'Errico 1928; Flecker 1933; McKern and Stewart 1957; Jit and Kularni 1976; Szilvassy 1980; Webb and Suchey 1985). It is generally considered that the presence of an epiphyseal surface (i.e. billowed ridge and furrow appearance) indicates the individual was under 25 years of age at death, and the absence of such a surface indicates the individual to be in excess of 25 years, as epiphyseal fusion has occurred. This is important, as apart from morphological changes at the pubic symphyseal surface, there are few reliable indicators of age at death beyond approximately 18-20 years. Considerable weight is therefore given to the presence of an epiphyseal surface at the medial end of the clavicle.

On a sample of 110 skeletons selected from the Western Reserve Collection, Stevenson (1924) found that epiphyseal union began in individuals aged 22 years and union was present in all individuals over the age of 28 years.

On a different sample from the same collection, Todd and D'Errico (1928) concluded that union may begin at around 20 years of age and completion will have occurred by the 25th year.

On a sample of 374 male individuals, McKern and Stewart (1957) found that epiphyseal union began at about 18 years of age, no individual would show complete fusion before 23 years of age and that total fusion would be expected in all individuals by 30 years of age.

Jit and Kulkarni (1976) examined the sternal end of the clavicle from radiographs of 684 individuals between the ages of 11 and 30 years. They concluded that. «A person showing a completely unfused epiphysis must be below 22 years of age in both sexes, and above 11 years if a female and 14 years if a male. An individual showing this epiphysis in a state of partial fusion must be

above 18 but below 24 years in age. A person showing complete fusion must be above 22 years of age».

Szilvassy (1980) identified three morphological phases at the medial end of the clavicle: — Phase 1 (18-20 years) the epiphyseal surface showed a pronounced granular appearance with horizontal ridging, Phase 2 (21-25 years) the ridged appearance had practically disappeared and a sharp border line was present about 1-2mm from the articular edge and Phase 3 (26-30 years) the surface was completely smooth and the border line had disappeared.

On an extensive sample of over 800 individuals, Webb and Suchey (1985) found absence of an epiphysis occurred through age 23 in females and age 25 in males. Non union with a separate epiphysis occurred at 16 through 21 years in females and 16 through 22 years in males. Union was first noted at 20 years of age in the female and 21 years in the male. Complete union in 100% of the sample occurred at 34 years for females and 31 years for males.

The timing and sequence of medial clavicular epiphyseal fusion is therefore of considerable importance in osteological analysis.

The aim of this investigation was to study the time and sequence of epiphyseal closure at the medial end of the clavicle in a previously unstudied documented skeletal collection of Portuguese origin.

MATERIAL

The human skeletal remains under investigation are housed in the Museu Bocage, Lisboa. The material is of documented sex, age at death, cause of death and occupation. Although the total number of skeletons in this collection will exceed 1650, at the time of study only some 400 had been cleaned, labelled and stored. Of these, full documentation was only available for some 200 individuals. It is anticipated that most, if not all, individuals will eventually possess full documentation. Although much work has still to be completed in the organisation of this collection, it will most certainly be invaluable for all workers in the field of human osteology.

Because of previous research on clavicular fusion, only individuals between the ages of 10 and 40 years were examined. Individuals were excluded if the medial aspect of the clavicle was fragmentary or if there was any evidence of gross pathological change.

This resulted in a final sample size of only 32 individuals (20 male and 12 female) with ages at death ranging from 11-39 years. The dates of birth of this sample ranged from 1881 to 1940 and the dates of death from 1918 to 1956.

All clavicles (right and left) were examined together to establish a serial sequence of epiphyseal closure. The identification numbers of individuals who died between the ages of 10 and 40 years were extracted from the records by an

independent observer. Thus, during the grading procedure, neither the sex or age at death of any individual was known to the author. The morphological appearance of the medial end of the clavicle was graded into five readily identifiable categories:

- Grade 1 - Distinct billowed ridge and furrow system present.
- Grade 2 - Ridge and furrow system present but not distinct, starting to show in-filling of the epiphyseal surface.
- Grade 3 - Indistinct ridge and furrow system still present, but an epiphyseal flake has commenced fusion to the diaphysis.
- Grade 4 - The epiphyseal flake has fused but a distinct line is still present marking the site of union. No ridge and furrow system present.
- Grade 5 - Complete epiphyseal fusion.

Sex specific variation in the sequence and timing of events was not considered due to the small sample size available for analysis.

RESULTS

Figure 1 shows illustrations of the medial end of the clavicle in the three individuals who showed epiphyseal flakes. It can be seen that the flake was most likely to be deficient on the infero-dorsal aspect.

Figure 2 illustrates the position of the epiphyseal flake in individual number 301.

Figure 3 shows the distribution in terms of age at death for the five different fusion grades. This was a blind test, in that the age of death of each individual was not known during the grading procedure. No difference in assigned grade was observed between right and left clavicles from any one individual.

It can be seen from figure 3 that a distinct billowed epiphyseal surface with no epiphyseal fusion was found in all individuals below 15 years of age and in one individual of that age. In no instance was this grade found in an older individual. A loss of distinct billowing with in-filling occurred in two individuals of 15 years but did not occur beyond the age of 21 years. Fusing epiphyseal flakes were found in only three individuals (those in figure 1) and all were 20 years of age at death. The fourth grade, where fusion was not complete but a fusion line was evident, occurred only in individuals between 24 and 27 years of age. Total epiphyseal fusion occurred in all individuals aged 29 and above.

DISCUSSION

The clavicle is an unusual bone in that, embryologically it is of dermal origin ossifying from condensed mesenchyme. The primary centres of ossification of the shaft appear at approximately 5-6 weeks of intra-uterine life and as such, are the first centres of ossification to appear. Ossification commences as intra-membranous, but due to transformation of the mesenchyme to pre-cartilage and then cartilage proper, ossification continues as endochondral. It has been suggested that this unusual progression of ossification may go some way towards explaining the delay found in epiphyseal fusion at the medial end of the clavicle (Williams and Warwick 1980).

However, no such delay is found at the lateral end of the clavicle, although there is some controversy as to whether or not an acromial epiphysis exists. If it does, its fusion appears to occur around puberty as in most other bones (Quain 1904).

The delay in fusion of the medial epiphysis of the clavicle is important when attempting to identify the age at death of a young adult. The results of this study suggest that «fusion» of the epiphysis to the diaphysis commences at approximately 20 years of age and is completed by the late twenties, thus displaying a delay in diaphysio-epiphyseal fusion of close to ten years compared to many other joints.

The results of this study suggest that there is a metamorphosis of the joint surface which appears to correspond well with progressing age at death, certainly in the Portugese sample.

Up until 15 years of age the epiphyseal surface appeared distinctly billowed which is the characteristic appearance of a growing surface. This billowing started to become less distinct at 15 years of age but billowing could still be discerned up to at least 21 years. However, around 20 years of age, the epiphysis started to fuse with the diaphysis. Of course fusion may occur earlier, as it is unlikely that all epiphyses either survived or were in fact retrieved. For

the epiphyseal flake to be present in archaeological material, it is suggested that fusion must be well established, so that the flake could not be accidentally removed. It is likely then that fusion would commence before 20 years of age. Established fusion (grade 4) was present in individuals aged between 24 and 27 years. In these individuals the flake had almost totally fused and there were no remnants of a billowed surface. By 29 years of age in all individuals the medial epiphysis of the clavicle had completely fused.

This morphogenesis closely mirrors events at the pubic symphysis, where distinct billowing is reduced firstly on the dorsal extremity and the fusion of epiphyseal structures (ossific nodules and the ventral rampart in the case of the symphysis) occurs at the ventral surface (Mckern and Stewart 1957). At the medial end of the clavicle, indistinct billowing is still to be observed on the dorsal aspect as the flake fuses with the superio-ventral aspect of the clavicular diaphysis.

From such a small sample size it cannot be confirmed whether the epiphysis is in all cases deficient infero-dorsally or if in fact in these three cases this area of the epiphysis was broken. It can however be confirmed that wherever a fusion line was present it occurred only at the superio-ventral aspect.

The sample size in this study was prohibitive to identifying a definitive progression of morphological changes at the sternal extremity of the clavicle. However, a well defined and easy to apply five stage method has been observed, which, on the basis of this blind test, may offer more reliable and definitive estimations of age at death in a relatively short range of ages at death (15-30 years).

Further work is required to firstly increase the sample size and in particular maximise the number of individuals between the ages of 15 and 29 years of age at death. Different skeletal samples also require to be examined to evaluate population variation.

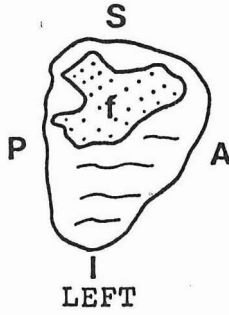
ACKNOWLEDGEMENTS

In particular, the author wishes to acknowledge the helpfulness of Dr. LMA Lopes and all staff in the Museu Bocage, UMDS for funding the research, Miss S Smith and Mr K Fitzpatrick for photography and the moral support of Dr L Scheuer and Miss R Ali.

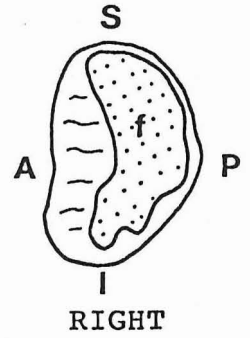
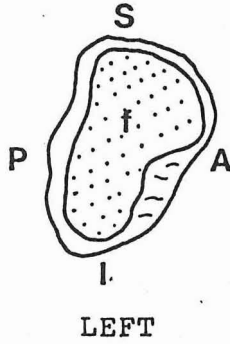
BIBLIOGRAPHY

- Flecker, H. 1933. Roentgenographic observations of the times of appearance of epiphyses and their fusion with the diaphysis. *J. Anat.*, 67, p. 118-164.
- Jit, I. e Kulkarni, M. 1976. Times of appearance and fusion of epiphysis at the medial end of the clavicle. *Indian. J. Med. Res.*, 64 (5), p. 773-782.
- Krogman, W.M. 1962. *The human skeleton in forensic medicine*. C. C. Thomas, Illinois.
- Krogman, W.M. e ISCAN, M.Y. 1986. *The human skeleton in forensic medicine*. CC Thomas, Illinois.
- Mckern, T.W. e Stewart, T.D. 1957. *Skeletal age changes in young American males*. Tech. report EP45, Quartermaster research and development center, Natick, Mass.
- Quain's elements of anatomy*. 1904. Osteology - arthrology, Volume II part I. Longmans, London.
- Stevenson, P.H. 1924. Age order of epiphyseal union in man. *Am. J. Phys. Anthropol.*, 7 (1), p. 53-93.
- Szilvassy, J. 1980. Age determination on the sternal articular faces of the clavícula. *J. Hum. Evol.*, 9, p. 609-610.
- Todd, T.W. e D'Errico, Jr. 1928. The clavicular epiphyses. *Am. J. Anat.*, 41, p. 25-50.
- Webb, P.A. e Suchey, J.M. 1985. Epiphyseal union of the anterior iliac crest and medial clavicle in a modern multiracial sample of American males and females. *Am. J. Phys. Anthropol.*, 68, p. 457-466.
- Williams, P.L. e Warwick, R. 1980. *Gray's Anatomy*. 36th edition, Churchill Livingstone, London.

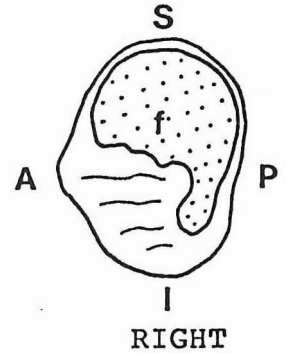
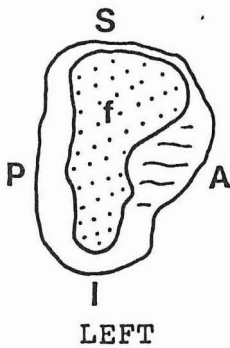
No. 301
Male aged 20
Died 1952



No. 314
Female aged 20
Died 1940



No. 391
Male aged 20
Died 1945



A = Anterior P = Posterior I = Inferior S = Superior

Fig. 1. Position of epiphyseal flake (f)

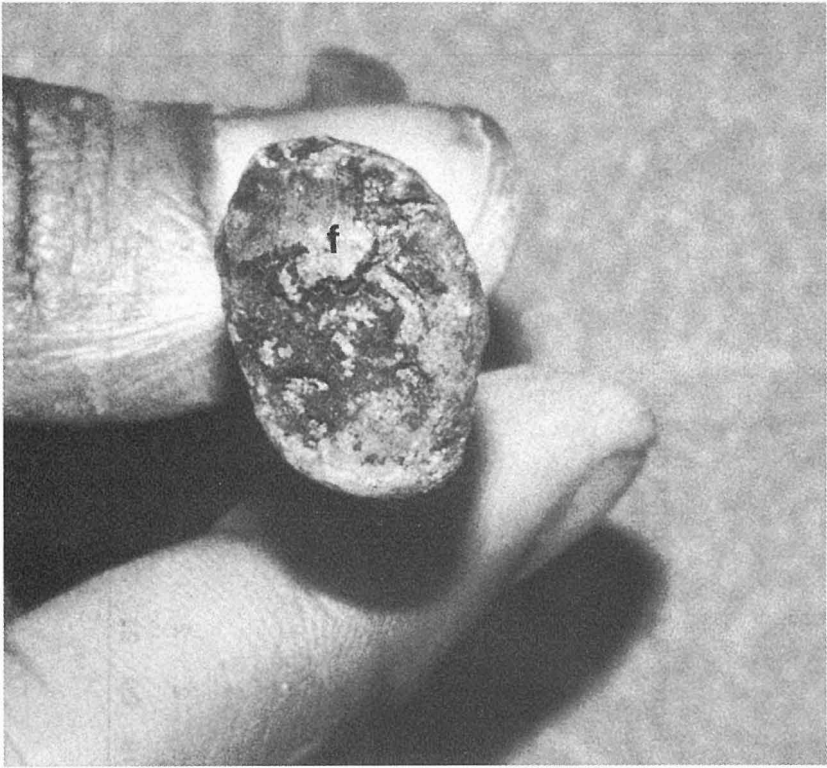

Fig. 2. Epiphyseal flake (f) on sternal end of clavicle from individual nº 301.

Figure 3. Distribution of fusion grades 1-5 (n=32)

n	9	7	5	3	1	11-14	15	16	17	18	19	20	21	22	23	24	25	26	27	28	29	30	31-39
5																							5
5																							5
5																							5
5																							5
5												3											5
5												3							4				5
5							2												4				5
3						1	2	2			2	3							4				5
1						1	1	2		2	2	2				4			4				5
						11-14	15	16	17	18	19	20	21	22	23	24	25	26	27	28	29	30	31-39